

Macrot textured Breast Implants with Defined Steps to Minimize Bacterial Contamination around the Device: Experience in 42,000 Implants

William P. Adams, Jr., M.D.

Eric J. Culbertson, M.D.

Anand K. Deva, F.R.A.C.S.

Mark R. Magnusson, M.D.

Craig Layt, F.R.A.C.S.

(Plast)

Mark L. Jewell, M.D.

Patrick Mallucci, M.D.,

F.R.A.C.S. (Plast)

Per Hedén, M.D.

Dallas, Texas; Sydney, Toowoomba,
and Gold Coast, Australia; Portland,
Ore.; London, United Kingdom; and
Stockholm, Sweden



Background: Bacteria/biofilm on breast implant surfaces has been implicated in capsular contracture and breast implant-associated anaplastic large-cell lymphoma (ALCL). Macrot textured breast implants have been shown to harbor more bacteria than smooth or micro textured implants. Recent reports also suggest that macrot textured implants are associated with a significantly higher incidence of breast implant-associated ALCL. Using techniques to reduce the number of bacteria around implants, specifically, the 14-point plan, has successfully minimized the occurrence of capsular contracture. The authors hypothesize that a similar effect may be seen in reducing the risk of breast implant-associated ALCL.

Methods: Pooled data from eight plastic surgeons assessed the use of macrot textured breast implants (Biocell and polyurethane) and known cases of breast implant-associated ALCL. Surgeon adherence to the 14-point plan was also analyzed.

Results: A total of 42,035 Biocell implants were placed in 21,650 patients; mean follow-up was 11.7 years (range, 1 to 14 years). A total of 704 polyurethane implants were used, with a mean follow-up of 8.0 years (range, 1 to 20 years). The overall capsular contracture rate was 2.2 percent. There were no cases of implant-associated ALCL. All surgeons routinely performed all 13 perioperative components of the 14-point plan; two surgeons do not routinely prescribe prophylaxis for subsequent unrelated procedures.

Conclusions: Mounting evidence implicates the role of a sustained T-cell response to implant bacteria/biofilm in the development of breast implant-associated ALCL. Using the principles of the 14-point plan to minimize bacterial load at the time of surgery, the development and subsequent sequelae of capsular contracture and breast implant-associated ALCL may be reduced, especially with higher-risk macrot textured implants. (*Plast. Reconstr. Surg.* 140: 427, 2017.)

CLINICAL QUESTION/LEVEL OF EVIDENCE: Therapeutic, IV.

The role of bacteria/biofilm on breast implant surfaces in potentiating the development of capsular contracture has been well established.¹⁻³ Interestingly, there are strong data that chronic inflammation from bacteria/biofilm is also responsible for the development of breast implant-associated anaplastic large-cell lymphoma (ALCL).^{4,5} To date, all confirmed cases have been of textured devices or patients with

multiple implants including at least one textured device.^{6,7} Originally, Brody pointed to a cause specific to Biocell macrot textured implants⁷; however,

Disclosure: Dr. Adams is an educational advisor for Allergan and Sientra, and was a clinical trial investigator for Allergan and Mentor. Dr. Deva is a consultant and research coordinator for Allergan, Mentor (Johnson & Johnson), and Acelity. Dr. Magnusson is a consultant for Allergan. Dr. Layt is an educational consultant for Allergan. Dr. Mallucci is an educational consultant for Allergan and a consultant for Sebbin and B-Lite. Dr. Hedén is a consultant and educational advisor for Allergan and a consultant for GC Aesthetics, Motiva/Establishment Labs, and B-Lite Implants. Drs. Culbertson and Jewell have no conflicts of interest to disclose.

From the Department of Plastic Surgery, University of Texas Southwestern Medical Center; Macquarie University and Integrated Specialist Healthcare; private practice; Oregon Health Science University; and Royal Free Hospital.

Received for publication January 3, 2017; accepted March 17, 2017.

Copyright © 2017 by the American Society of Plastic Surgeons

DOI: 10.1097/PRS.0000000000003575

implant demographics have demonstrated this to occur in multiple different types of textured devices. This is a logical observation, given that textured devices harbor exponentially more bacteria than smooth implants,² and this is associated with greater lymphocyte stimulation.⁴ Implant surface texturing varies by manufacturer, and can generally be classified as macrot textured, including polyurethane and Biocell (Allergan plc, Dublin, Ireland), intermediate-textured (TRUE Texture; Sientra, Santa Barbara, Calif.), or microtextured (Siltext; Mentor Worldwide, Santa Barbara, Calif.).^{8,9} More aggressive macrot textured implants (polyurethane and Biocell) demonstrate higher bacterial counts than those with less aggressive texturing (Siltext and Poly Implant Prothèse), and a greater T-cell response.⁴ Chronic T-cell activation in response to the implant bacteria/biofilm may be the inciting factor in implant-associated ALCL, and may explain why it has only been reported in association with textured implants. Recent reports in Australia have indicated a significantly higher calculated incidence in macrot textured implants (one in 2400 to one in 4500).¹⁰

Techniques to reduce the number of bacteria around implants have minimized the occurrence of capsular contracture to very low levels, less than 1 percent.^{1,3,11–13} Similar to cutaneous ALCL, which has a pathway of transformation through a bacterial superantigen,¹⁴ breast implant-associated ALCL is hypothesized to undergo a similar process. Furthermore, the same techniques that reduce the bacterial load/contamination around implants—specifically, the 14-point plan (Table 1)—will likely reduce the risk of implant-associated ALCL. The purpose of this study was to look at a global experience in macrot textured devices with regard to implant-associated ALCL among a group of surgeons who use similar surgical technique, including the 14-point plan.

PATIENTS AND METHODS

Eight plastic surgeons in five countries collected their prospective macrot textured implant experience looking at technique and the incidence of breast implant-associated ALCL. Patients were followed according to the protocol of the individual practice; however, this included yearly documented follow-up as standard practice. The data for the total number of macrot textured implant (Biocell, polyurethane) patients were combined for all surgeons, total number of implants placed, mean follow-up, type of case performed, total number of cases of breast implant-ALCL that has developed among their patients, and adherence to each component of the 14-point plan used in their practices (Table 1).

RESULTS

The overall experience is reported in Table 2. A total of 42,035 Biocell implants were placed in 21,650 patients, with a mean follow-up of 11.7 years (range, 1 to 14 years). A total of 704 polyurethane-covered implants were used in 352 patients, with a mean follow-up of 8.0 years (range, 1 to 20 years). All surgeons reported using Biocell implants; six (75 percent) had also placed polyurethane implants. The majority of these implants were used in primary breast augmentation (77.9 percent), followed by augmentation mastopexy (9.9 percent), revision augmentation (8.2 percent), and breast reconstruction (4.0 percent). The overall capsular contracture rate was 2.2 percent. There were no cases of implant-associated ALCL.

All surgeons routinely performed all perioperative components of the 14-point plan at the time of implant placement. Six of the surgeons adhered to all 14 steps during placement of 10,359 implants (24.2 percent). The remaining

Table 1. Surgical 14-Point Plan for Breast Implant Placement

1. Use intravenous antibiotic prophylaxis at the time of anesthetic induction.
2. Avoid periareolar/transaxillary incisions; these have been shown in both laboratory and clinical studies to lead to a higher rate of contracture.
3. Use nipple shields to prevent spillage of bacteria into the pocket.
4. Perform careful atraumatic dissection to minimize devascularized tissue.
5. Perform careful prospective hemostasis.
6. Avoid dissection into the breast parenchyma.
7. The use of a dual-plane pocket.
8. Perform pocket irrigation with correct proven betadine triple-antibiotic solution, non-betadine triple or 50% (1:1 dilution) or stronger povidone-iodine.
9. Steps to minimize skin contamination (e.g., wipe/prep skin, barrier, sleeve).
10. Minimize implant open time and replacement of implant or sizers.
11. Change surgical gloves before handling and use new or cleaned instruments and drapes.
12. Avoid using a drainage tube, which can be a potential site of entry for bacteria (augmentation).
13. Use a layered closure.
14. Use antibiotic prophylaxis to cover subsequent procedures that breach skin or mucosa.

Table 2. Pooled Experience of Eight Surgeons with Biocell and Polyurethane Textured Breast Implants

	Value
Biocell	
Total no. of implants placed	42,035
Total no. of patients	21,650
Mean follow-up, yr	11.7
Polyurethane	
Total no. of implants placed	704
Total no. of patients	353
Mean follow-up, yr	8
Type of case, %	
Primary augmentation	77.9
Augmentation mastopexy	9.9
Augmentation revision	8.2
Breast reconstruction	4.0
Mean capsular contracture rate	2.2
Total cases of BIA-ALCL	0

BIA-ALCL, breast implant-associated ALCL.

two surgeons followed 13 of the steps in 32,380 cases (75.8 percent), but did not routinely use or recommend antibiotic prophylaxis for subsequent procedures that breach skin or mucosa such as dental procedures.

DISCUSSION

Bacterial/biofilm primarily forms on the implant surface dependent on the presence of initial bacterial contact with the implant surface at the time of surgery.¹ The extracellular slime provides relative isolation from antibiotics and limits exposure to the host immune response. Although

theoretically designed to promote periprosthetic capsular tissue ingrowth to increase adherence to the capsule and limit implant mobility, the irregular surface and increased surface area of textured implants provide a harbor for bacterial growth and biofilm formation. Hu et al.⁴ demonstrated that a chronic immune response is elicited by bacterial biofilm, characterized by a predominant T-cell lymphocytic infiltrate. They found that textured implants harbored significantly more bacteria than smooth implants, and are associated with significantly greater lymphocytic infiltrate. The most popular macrotextured breast implants, Biocell and a smaller percentage of polyurethane devices, have the greatest bacterial growth and lymphocytic response compared with less textured (microtextured) implants. This is logical, given that more aggressive texturing provides a space for bacterial growth. Although breast implant-associated ALCL is likely a separate entity from systemic ALCL, and shares many similarities to primary cutaneous ALCL, they are all characterized by T-cell derivation.^{15,16} Further supporting bacterial biofilm as the inciting cause of implant-associated ALCL, Hu et al.⁵ recently identified the unique microbiome of *Ralstonia* spp. in ALCL specimens compared with normal and contracture capsule specimens (primarily Gram-positives), and in the breast implant-associated ALCL subgroup who also had contralateral non-breast implant-associated ALCL capsular pathology found significantly

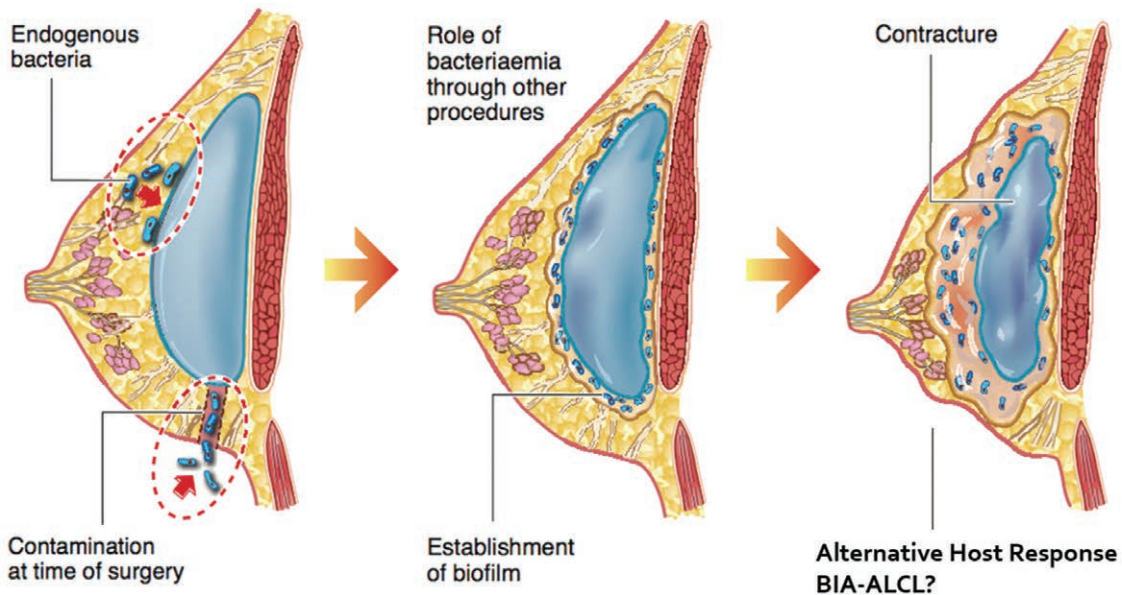


Fig. 1. Bacterial contamination at the time of breast implant placement, from endogenous bacteria or from seeding through transient bacteremia, may contribute to biofilm formation and subsequent inflammation. Long-term sequelae include capsular contracture and a sustained T-cell response that may lead to breast implant-associated ALCL (BIA-ALCL).

lower bacterial concentration in normal contralateral capsule specimens. Furthermore, all reported cases of implant-associated ALCL to date have been in association with textured implants.⁶

Chronic stimulation by bacterial antigens, a sustained T-cell response, and genetic transformation appear to constitute the basic model for development of implant-associated ALCL (Fig. 1).¹⁶ Interestingly, the same pathogenesis is seen in primary cutaneous ALCL.¹⁴ Although there is now very compelling evidence for a chronic immune response to bacterial/biofilm as the primary mechanism of transformation to breast implant-associated ALCL, there is growing controversy over the classification of this disease.^{7,17} Although the initial classification of ALCL by the World Health Organization originally took a conservative approach, the “decision makers” were primarily not people who treat breast implant patients. The consensus from many international breast implant experts is that it is very obvious that this entity behaves not like an ALCL but rather like a lymphoproliferative disorder. Specimens isolated from implant capsules consistently demonstrate anaplastic cytology and CD30⁺ antigen expression, consistent with ALCL. However, systemic ALCL typically expresses anaplastic lymphoma kinase especially in younger patients, whereas breast implant-associated ALCL is anaplastic lymphoma kinase-negative in the majority of cases.¹⁸ In most cases of implant-associated ALCL, the tumor is confined to the seroma fluid only and/or implant capsule, but axillary and/or mediastinal metastases and disseminated disease have been reported.⁷ It is typically characterized by a more indolent course, and is frequently treated by capsulectomy alone. Breast implant-associated ALCL shares many similarities to primary cutaneous ALCL, which is also anaplastic lymphoma kinase-negative and commonly presents with localized lesions with infrequent spread to lymph nodes and overall excellent prognosis.^{15,16} Breast implant-associated ALCL appears to be a distinct entity from systemic ALCL, with many features in common with primary cutaneous ALCL, and likely will warrant a new classification as a lymphoproliferative disorder. Nevertheless, minimizing contamination at the time of surgery and the load of bacteria that lead to biofilm formation (the 14-point plan)¹ reduces the known sequelae of bacteria/biofilm and breast implants. The “14-point effect” has been proven for capsular contracture.^{1,3,11–13,19,20}

In light of recent evidence that implicates a higher incidence of breast implant-associated ALCL in macrot textured devices,¹⁰ the data in this article demonstrate that technique is a critical

factor in the use of textured implants, and most importantly macrot textured implants. Although the extrapolation is not fully valid, as not all of the patients in this series were treated in Australia, the expected number of implant-associated ALCL cases would be between eight and nine diagnoses; however, there were no cases in this series. The series approaches 43,000 macrot textured implants, with a mean follow-up of 11.7 and 8.0 years in patients with Biocell and polyurethane implants, respectively, and provides adequate average follow-up to comment on implant-associated ALCL. Polyurethane was included, because it is the other main macrot textured implant type.

As with capsular contracture, where the 14-point plan techniques have reduced capsular contracture rates to 1 percent or less,^{11–13} this study seeks to specifically review the experience with breast implant-associated ALCL in macrot textured implants from a group of international surgeons using similar techniques. Supporting this logic is the capsular contracture rate of 2.2 percent in the same group of patients. This study was not meant to be an exhaustive analysis of the relationship of implant placement technique and ALCL, but was intended simply to demonstrate that surgeons using systematic, defined, and evidence-based principles have achieved a low rate of implant-associated ALCL (specifically, zero cases) in a large number of implants at highest risk.

CONCLUSIONS

Although debate remains over the cause and classification of breast implant-associated ALCL, mounting evidence clearly implicates a prominent and likely key role of implant bacteria/biofilm and associated host immune response. Using the principles of the 14-point plan to minimize the bacterial load at the time of surgery, the development and subsequent sequelae of capsular contracture and breast implant-associated ALCL may be reduced, especially with higher risk textured implants.

William P. Adams, Jr., M.D.

Department of Plastic Surgery
University of Texas Southwestern Medical Center
6901 Snider Plaza, Suite 120
Dallas, Texas 75205
wpajrmd@dr-adams.com

REFERENCES

1. Deva AK, Adams WP Jr, Vickery K. The role of bacterial biofilms in device-associated infection. *Plast Reconstr Surg*. 2013;132:1319–1328.

2. Jacombs A, Tahir S, Hu H, et al. In vitro and in vivo investigation of the influence of implant surface on the formation of bacterial biofilm in mammary implants. *Plast Reconstr Surg*. 2014;133:471e–480e.
3. Adams WP Jr. Capsular contracture: What is it? What causes it? How can it be prevented and managed? *Clin Plast Surg*. 2009;36:119–126, vii.
4. Hu H, Jacombs A, Vickery K, Merten SL, Pennington DG, Deva AK. Chronic biofilm infection in breast implants is associated with an increased T-cell lymphocytic infiltrate: Implications for breast implant-associated lymphoma. *Plast Reconstr Surg*. 2015;135:319–329.
5. Hu H, Johani K, Almatroudi A, et al. Bacterial biofilm infection detected in breast implant-associated anaplastic large-cell lymphoma. *Plast Reconstr Surg*. 2016;137:1659–1669.
6. U.S. Food and Drug Administration; Center for Devices and Radiological Health. *Anaplastic large cell lymphoma (ALCL) in women with breast implants: Preliminary FDA findings and analyses*. Available at: <https://www.fda.gov/medicaldevices/productsandmedicalprocedures/implantsandprosthetics/breastimplants/ucm239996.htm>. Accessed June 28, 2017.
7. Brody GS, Deapen D, Taylor CR, et al. Anaplastic large cell lymphoma occurring in women with breast implants: Analysis of 173 cases. *Plast Reconstr Surg*. 2015;135:695–705.
8. Abramo AC, De Oliveira VR, Ledo-Silva MC, De Oliveira EL. How texture-inducing contraction vectors affect the fibrous capsule shrinkage around breasts implants? *Aesthetic Plast Surg*. 2010;34:555–560.
9. Maxwell GP, Schefflan M, Spear S, Nava MB, Hedén P. Benefits and limitations of macrot textured breast implants and consensus recommendations for optimizing their effectiveness. *Aesthet Surg J*. 2014;34:876–881.
10. Loch-Wilkinson A, Beath K, Knight RJW, et al. Breast implant associated anaplastic large cell lymphoma in Australia and New Zealand: Higher risk for macrot textured implants supports a bacterial etiology. *Plast Reconstr Surg*. (in press).
11. Adams WP Jr, Rios JL, Smith SJ. Enhancing patient outcomes in aesthetic and reconstructive breast surgery using triple antibiotic breast irrigation: Six-year prospective clinical study. *Plast Reconstr Surg*. 2006;117:30–36.
12. Blount AL, Martin MD, Lineberry KD, Kettaneh N, Alfonso DR. Capsular contracture rate in a low-risk population after primary augmentation mammoplasty. *Aesthet Surg J*. 2013;33:516–521.
13. Giordano S, Peltoniemi H, Lilius P, Salmi A. Povidone-iodine combined with antibiotic topical irrigation to reduce capsular contracture in cosmetic breast augmentation: A comparative study. *Aesthet Surg J*. 2013;33:675–680.
14. Linnemann T, Gellrich S, Lukowsky A, et al. Polyclonal expansion of T cells with the TCR V beta type of the tumour cell in lesions of cutaneous T-cell lymphoma: Evidence for possible superantigen involvement. *Br J Dermatol*. 2004;150:1013–1017.
15. de Leval L, Gaulard P. CD30+ lymphoproliferative disorders. *Haematologica* 2010;95:1627–1630.
16. Kadin ME, Deva A, Xu H, et al. Biomarkers provide clues to early events in the pathogenesis of breast implant-associated anaplastic large cell lymphoma. *Aesthet Surg J*. 2016;36:773–781.
17. Xu J, Wei S. Breast implant-associated anaplastic large cell lymphoma: Review of a distinct clinicopathologic entity. *Arch Pathol Lab Med*. 2014;138:842–846.
18. Popplewell L, Thomas SH, Huang Q, Chang KL, Forman SJ. Primary anaplastic large-cell lymphoma associated with breast implants. *Leuk Lymphoma* 2011;52:1481–1487.
19. Adams WP Jr, Mallucci P. Breast augmentation. *Plast Reconstr Surg*. 2012;130:597e–611e.
20. Wiener TC. The role of betadine irrigation in breast augmentation. *Plast Reconstr Surg*. 2007;119:12–15; discussion 16–17.